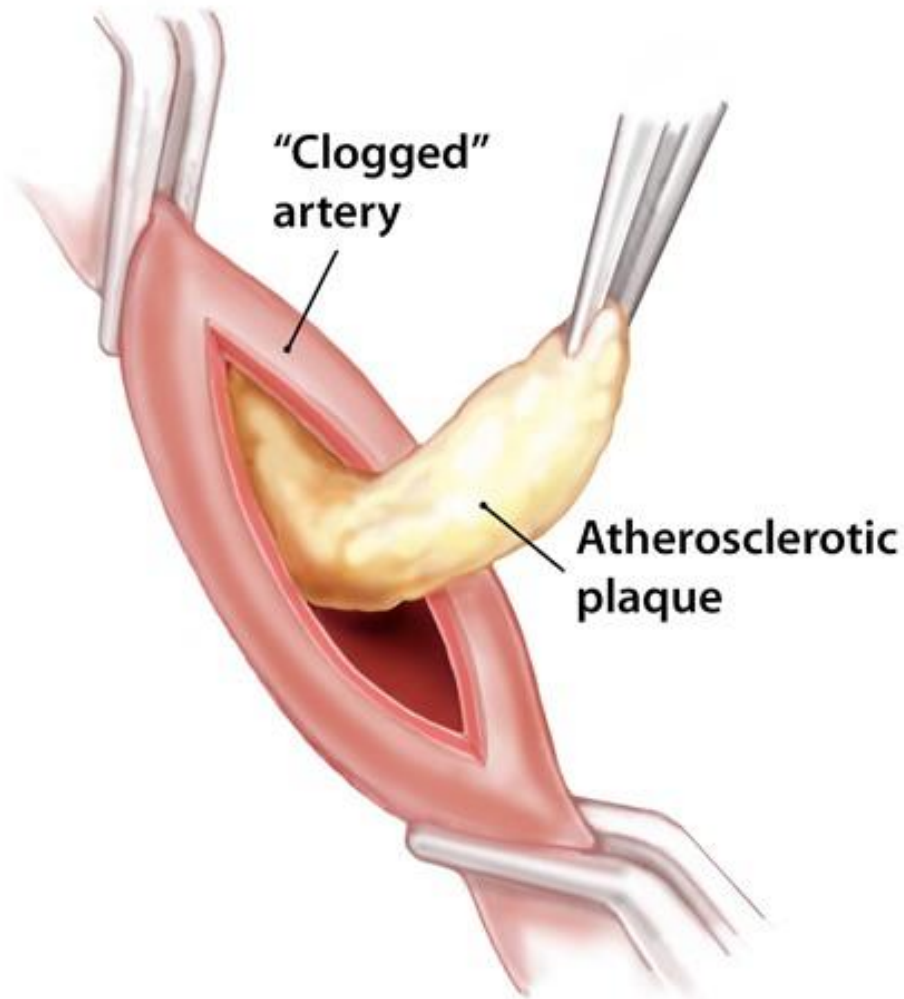


Common Femoral Endarterectomy and Patch.



Mr. Matthew Claydon

Vascular and Endovascular Surgeon

M.B., B.S.(Hons), B.Med.Sci.(Hons)
F.R.A.S.C.S.(General), F.R.A.C.S.(Vascular)

The Disease

Arteries take blood, carrying vital **oxygen and nutrients**, to the tissues of the body.

The leg has several main arteries and a network of smaller arteries (called collaterals). The main arteries can be likened to the highways and the collaterals can be likened to side roads

If there is insufficient blood supply, the tissues are deprived of oxygen and nutrients. This can cause **pain and dysfunction** during activity or in more severe cases **pain at rest, ulceration** and tissue death including **gangrene**.

The commonest cause of narrowing and blockage of the arteries is **atherosclerosis** (hardening of the arteries). Atherosclerosis is a complex deposition of fats and calcium in the artery wall.

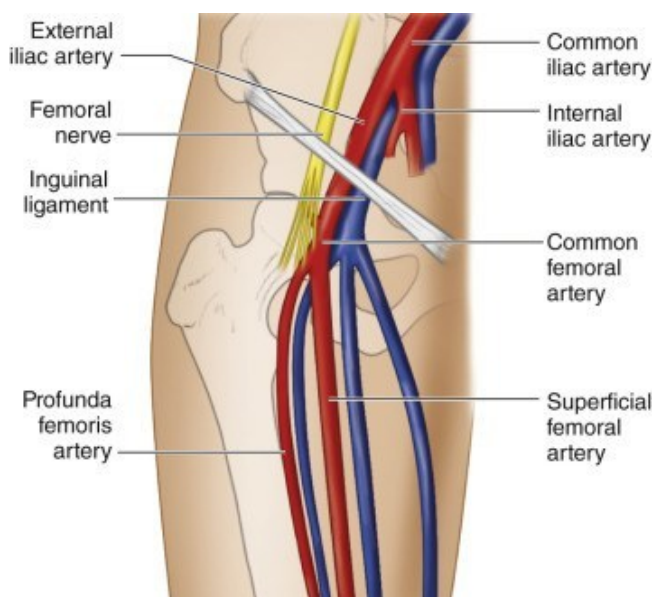


Figure 1. The femoral arteries in the groin.

Symptoms and Complications

- **Claudication** - Pain in the leg muscles during exercise.
- **Rest Pain** – often at night. This is more often in the foot near the toes. It is often relieved by hanging the leg down.
- **Ulceration/Non-healing Wounds** - This occurs when the blood supply is insufficient to keep the skin alive, especially in areas of increased load or after wounding.
- **Neurological** change such as tingling or numbness or even paralysis. Severe pain, numbness, tingling or paralysis is an **emergency** requiring immediate treatment.
- **Colour** changes in the foot/toes

Claudication can be a minor annoyance or a **debilitating** symptom. The risk of ultimate limb loss is small in people suffering only claudication.

Rest pain, ulceration and gangrene can signal impending limb loss. This is critical limb ischaemia and is a strong indication for treatment.

Investigations

There are multiple investigations used for the investigation of arterial disease. These include:-

- **Duplex Ultrasound Scan**
- **Doppler pressure studies** with an ultrasound probe and blood pressure cuff applied to the arm, leg and toes.
- **Exercise Doppler pressure studies** – pressure studies are done before and after exercise.
- **Angiography** with X-Ray contrast injection into the artery
- **CT or MRI Scans**

Treatment Options

- **Conservative Management** and risk factor control including exercise therapy.
- **Endoluminal treatment** with balloon angioplasty ± stent placement.
- **Surgical Endarterectomy** – a removal of a focal narrowing from the artery.
- **Arterial Bypass Surgery**
- **Sympathectomy** – a procedure to destroy some of the nerves to provide some temporary relief.
- **Major and Minor Amputation**
- A **Combination** of the above

The treatment depends on the nature and location of the pathology, the symptoms experienced, levels of previous and current activity and patient choices.

Femoral Endarterectomy and Patch

Femoral Endarterectomy surgery is usually selected when there is a focal blockage or narrowing in the **femoral artery** in the groin (see *figure 1*). The surgery removes the narrowing in the artery and makes the artery slightly larger to allow more blood flow through it.

Spare vein is usually used for this, either from the leg or an arm. Occasionally a plastic patch is used.

Under **anaesthetic**, an incision is made in the groin over the artery. A separate small cut may be made in either the leg or the arm to



harvest a small length of vein used to create a patch. The **narrowed artery** is dissected out, including the artery/s above and below it for clamping. Blood thinning medication is given before the blood flow is temporarily interrupted with either clamps or balloons to allow the surgery to be performed.

A longitudinal cut is made in the artery through the narrowing and the **atherosclerosis is carefully removed** from the inside of the artery. The artery is closed using a **patch** to ensure the artery is of a normal size after the closure is complete. (See Figure 2). The joins are inspected before drains are placed and the cuts sewn closed, usually with dissolving stitches.

Expectations

The results from surgery depend on a number of factors, including:-

- The extent of atherosclerosis
- The quality, size and number of the vessels above and below the blockage
- The symptoms suffered by the patient.
 - Re-do surgery is generally more difficult.

Usually, an excellent result is achieved with relief of the symptoms by the procedure, with only a small scar.

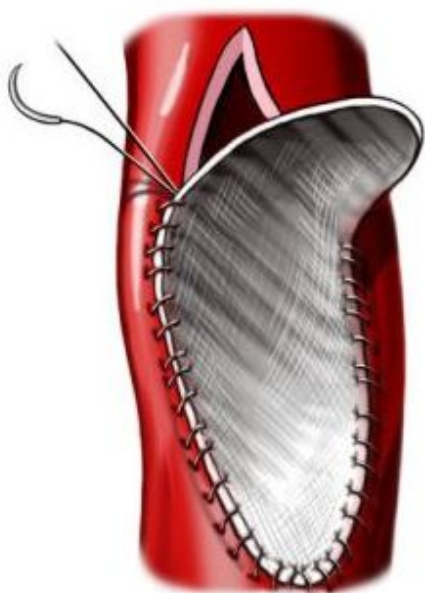


Figure 2. Femoral Arterial Patch

Side effects and Complications

Unfortunately, no invasive treatment is perfect or without risk. While not exhaustive the more common and important risks are outlined below.

Potential risks include the general risks of anaesthesia and surgery:-

- **Death**
- **Heart Attack**
- **Stroke**
- **Renal Failure**
- **Wound Infection (5-15%)**
- **Deep Venous Thrombosis**
- **Pulmonary Embolus**
- **Excessive Scarring**

The specific risks of the surgery include:-

- **Failure** to improve the blood supply.
- **Worsening of blood flow** to the leg.
 - Very calcified, diseased arteries are fragile and can be damaged with minimal manipulation.
- **Bleeding** and requirement for blood transfusion.
- **False Aneurysm** formation which is a ballooning of the artery which may require further surgery in the future.
- **Sensory nerve damage** causing numbness, tingling or pain.
- Rarely, **motor nerve damage** causing weakness can occur.
- **Graft Infection** requiring further surgery.
- **Recurrent narrowing** with time leading to the recurrence symptoms.
- **Progression of disease** in arteries above or below the bypass.
- **Lymphatic leak** - a clear fluid which usually flows in very small tubes which can leak from the wound. Occasionally requires further surgery.
- **Swelling leg** – common, may last weeks → months.

Website:

arteryandvein.com.au

Email:

info@arteryandvein.com.au

Phone:

9576 1491

